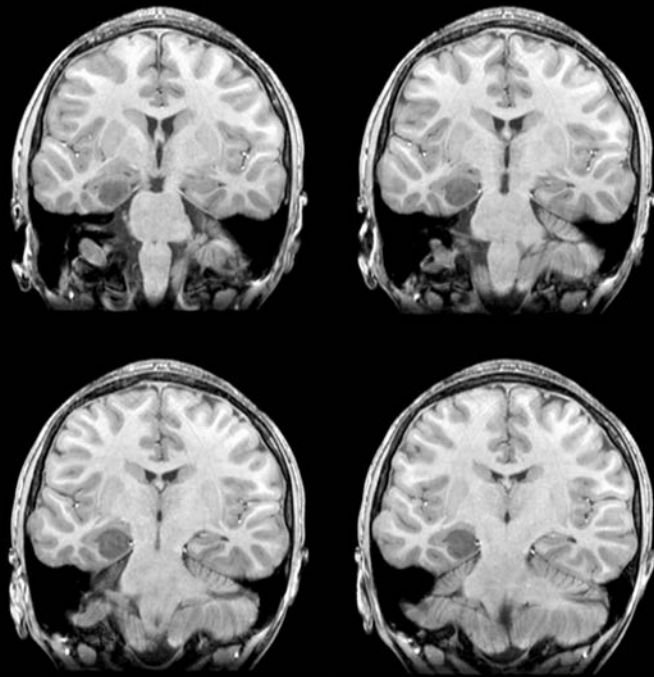


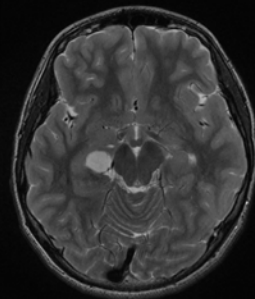
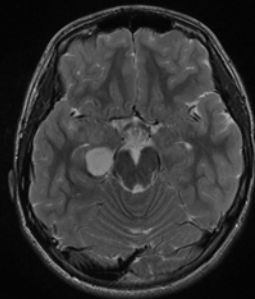
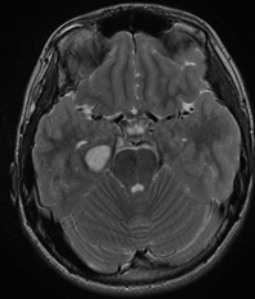
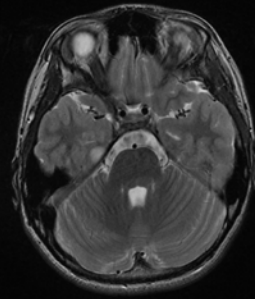
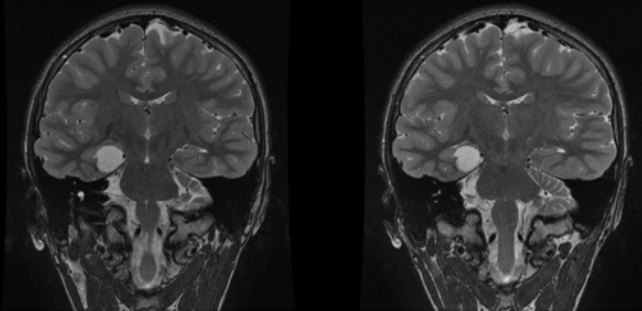
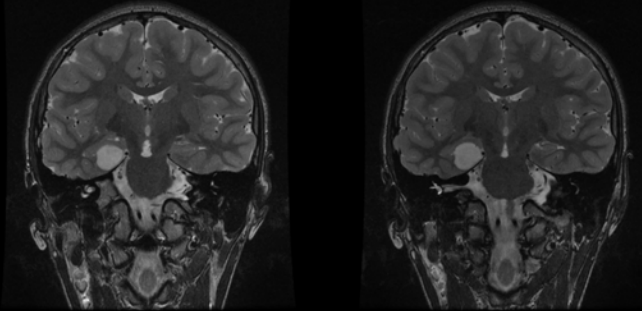
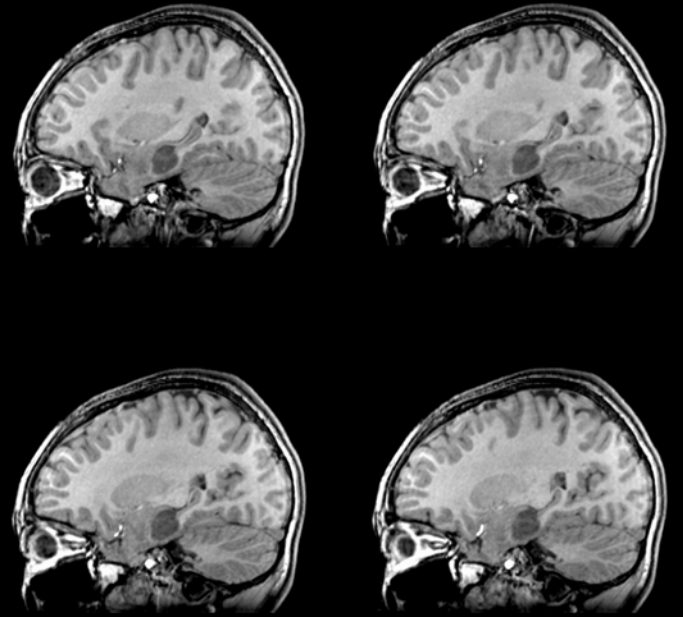
症例1

- 12才男児 側頭葉てんかんで発症

症例 1



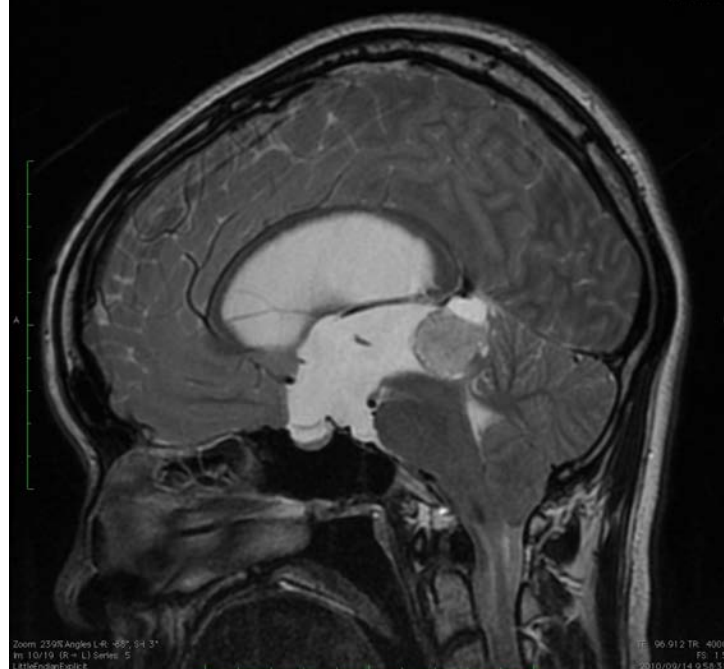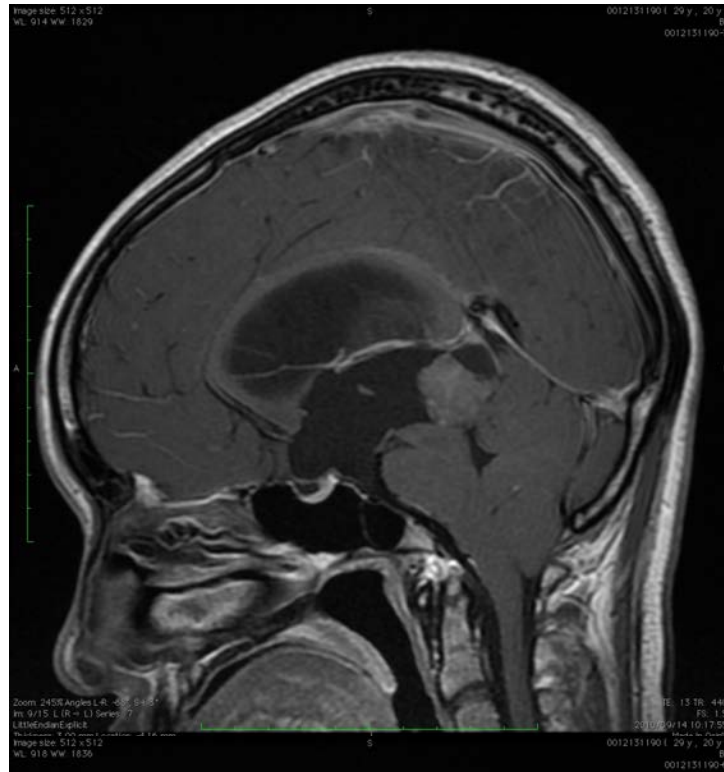T1 coronal / sagittal
T2 coronal / axial



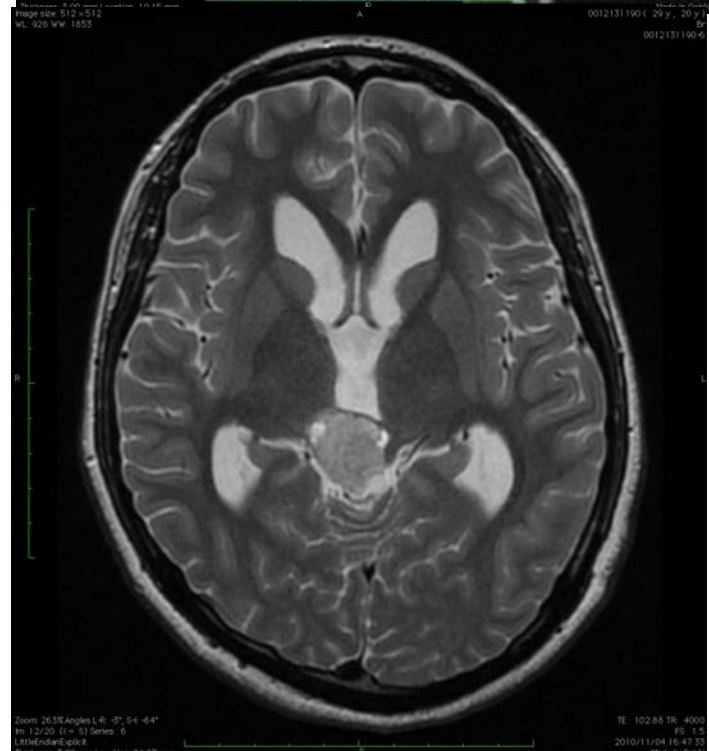
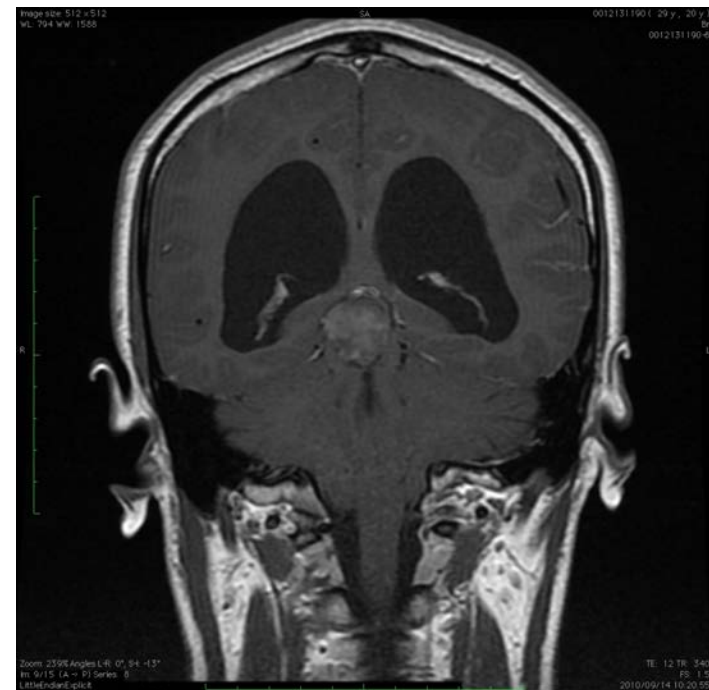症例2

- 20才女性 吹奏楽でチューバを吹くと頭痛があり発見された水頭症
- 内視鏡下第3脳室底開窓術と同時施行された腫瘍生検で pineal parenchymal tumor of intermediate differentiation (WHO grade II-III) と診断される

症例2

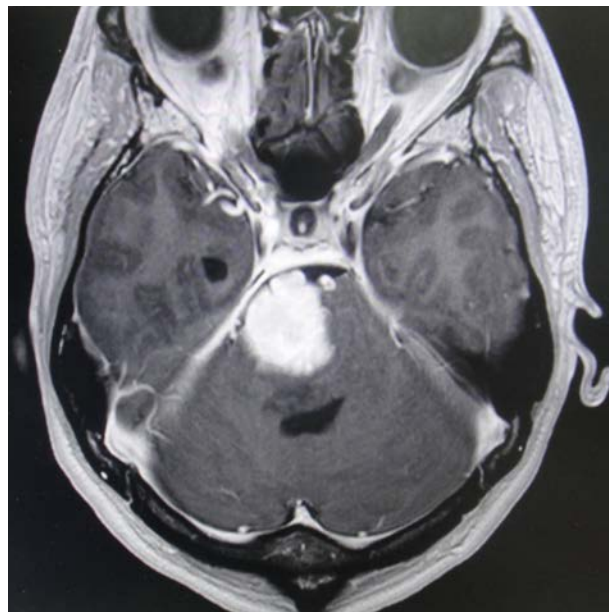
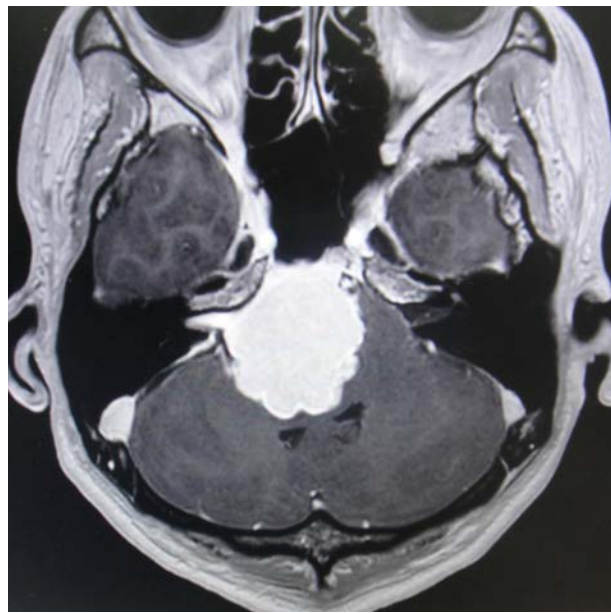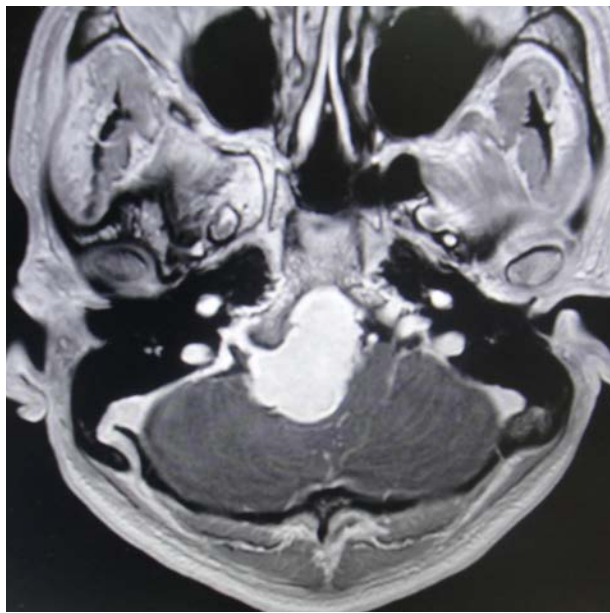


T1 Gd(+) sagittal / coronal
T2 sagittal / axial



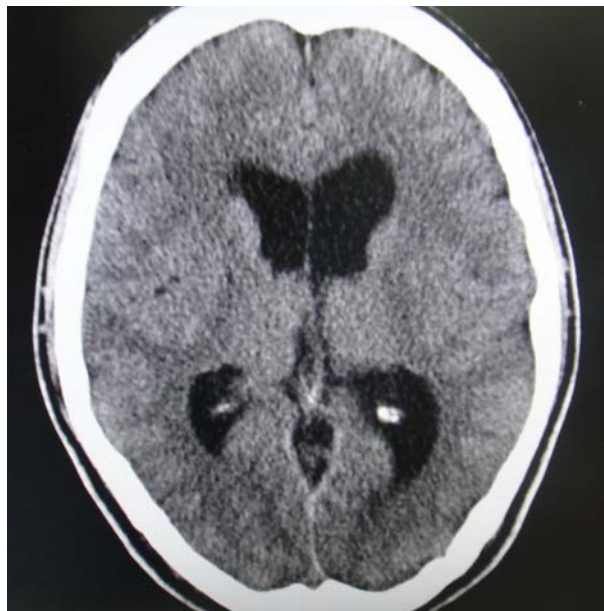
症例3

- 30代 男性 数ヶ月来進行する頭痛と嘔下
困難

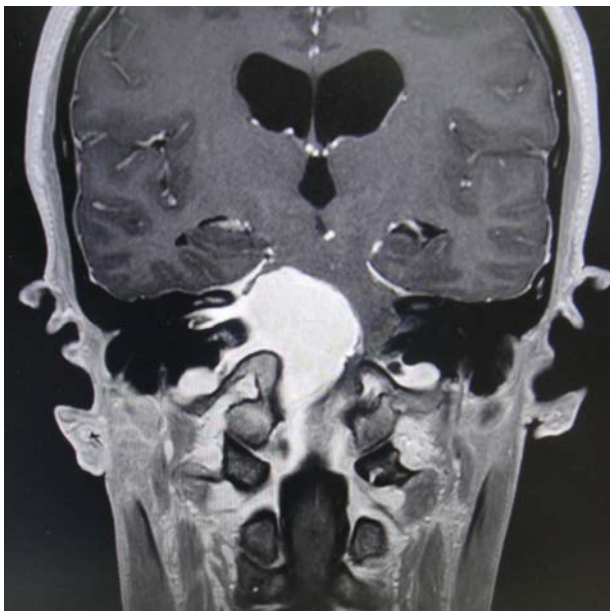


症例3

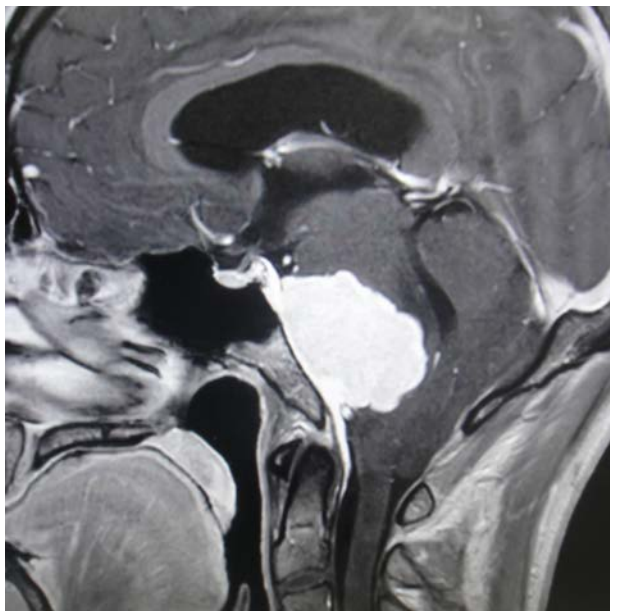
Gd(+) axi



CT axi



Gd(+) cor



Gd(+) sag